International Journal of Clinical Implant Dentistry, January-April 2009;1(1):32-39

Oral Spirochetosis Associated with Dental Implants: Important Clues to Systemic Disease

William D Nordquist

DDS, Private Practice, 2304 6th Avenue, San Diego, California-92101, USA

Abstract: A completely different understanding of oral infection and its relationship to systemic disease, including atherosclerotic heart disease, will be presented. Convincing evidence theorizes the mechanism involved with atherosclerotic heart disease and oral spirochetes. Multiple missing teeth, heart disease, diabetes, dementia and many other diseases are all related to spirochetes. The discoveries reported here were direct results of studies done to avoid and eliminate infection around dental implants. Oral spirochetal infections when treated with antibiotics create an increasing hostile environment that when not lethal to the bacteria will stimulate a rapid transition to a protective spore form, especially in granulation tissue. Morphologically identical spores were found in the atherosclerotic plaque in blood vessels. A review of other spirochetal diseases traces a one hundred year trail of evidence that leads to oral spirochetes as a major contributory factor in systemic disease.

Keywords: Spirochetes, dental implants, systemic diseases, periodental disease.

INTRODUCTION

Spirochetal diseases, including those diseases caused by oral spirochetes, have many similarities. The two most infamous of these diseases are Syphilis and Lyme disease. These diseases both have initial local invasion of the spirochete that results in a small lesions. It is critical that these initial symptoms be immediately diagnosed and treated. If not diagnosed early and treated successfully with antibiotics the spirochete will gain access via the circulatory system and disseminated to other tissues of the body. There they convert into a dormant stage. Later in life when conditions are ripe, they will re-emerge causing devastating disease. Both diseases are extremely difficult, if not impossible, to treat if not caught early. Syphilis progresses in stages with the third stage characterized by a set of peculiar skin affections, including scabby skin boils, gumma, which can occur anywhere in the body, successive crops of bubbles, which eventually dissipate leaving dark spots on the skin.[1] It also is associated with bone lesions identical to bone lesions caused by advanced periodontal disease and also Lyme disease.

A study of Lyme disease is very sobering and causes similar problems for victims, as syphilis. The medical community is deeply divided regarding the treatment of Lyme disease. Evidently, this disease is very persistent and is not always cured by the initial treatment. It has a secondary phase similar to syphilis. No single antibiotic or combination of antibiotics appears to be capable of completely eradicating the infection, and treatment failures or relapses are reported with all current regimens, although they are less frequent with early aggressive treatment.[2] This is one more spirochete that seems to have secondary complications when the spirochetes themselves gain access to the bloodstream to disseminate throughout the body and causes problems.[3]

Once the spirochete gains access and is distributed via the bloodstream to other tissues of the body, it becomes impossible to eliminate. Late sequester of these two spirochetal bacteria cause abscesses, bone lesions, and mental problems later in life. It just depends on the tissue or organ that the spirochete takes up residence once it gains access. Oral spirochetosis, for lack of a better term, describes the systemic consequences of oral spirochetes. Most patients that present for implant dentistry treatment with multiple missing teeth have multiple health problems. Some of these health problems are strikingly similar to Syphilis and Lyme disease. Other symptoms are not as intuitively obvious until they are analyzed. If spirochetes can cause disease in the known sequester of Syphilis and Lyme disease, then oral spirochetes have an increased potential to cause disease in a similar fashion. Periodontal disease is common among patients and oral spirochetes have years to gain access via multiple bacteremias into the bloodstream and into the body's tissues. That explains why patients who have multiple missing teeth resulting from chronic periodontal disease also have so many different system problems. Their list of diseases includes:

1. Atherosclerosis which includes patients whose health history including;
   a. ***Heart disease***: Many studies that have linked heart disease to periodontal disease have been in the dental literature background for several years.[4-12] These patients relate the stories of heart attacks, by-pass surgeries, and stents being placed by cardiologists. These patients are on blood thinners, aspirin, and cholesterol lowering medicines.

b. ***High blood pressure:*** These patients are on one of a number of different types of high blood pressure medicine.

c. ***Stroke:*** These patients have had high blood pressure and are on the same medicines mentioned above.

d. ***Dementia:*** Smithe and Riviere[13] found evidence of oral Treponema in the brain of Alzheimer's disease patients. Miklossy[14] observed spirochetes in the blood of people with Alzheimer's disease. This is additional evidence that oral spirochetes may cause or contribute to plaque forming neurological diseases. These patients are probably in the early stages of Alzheimer's disease. These patients make implant dentistry almost unbearable for clinicians who do not understand this problem and its relationship to implant dentistry. These patients cannot reason properly, but most do not even realize that they are impaired. If treatment does not go according to plan or when problems occur and sometimes for no reason at all, these patients have difficulty in understanding the problem and/or treatment necessary to mitigate a problem. This makes the practice of implant dentistry unique among the dentistry disciplines in that implant dentists need to be able to deal with these psychological problems.

2. ***Diabetes:*** Many of these patients are on the various drugs from insulin to drugs that stimulate the pancreas to produce more insulin to patients controlled by diet. As long as they are controlled, implant dentistry can proceed normally. Periodontal disease and diabetes are also related diseases.[15]

3. ***Multiple missing teeth:*** Since periodontal disease is related to heart disease it follows that these patients have many missing teeth. And in fact the literature supports this theory.[16-19] As a result of these missing teeth, these are the patients who make-up the base for implant dentistry practices. I am not sure, however, that most dentists practicing on these patients understand the full ramifications and implications of the diseases these patient present. Judging from the merits of lawsuits these patients bring to bear on their dentists, some of these patients do not comprehend what the dentist has to go through to complete an implant dentistry case successfully. Also, these patients do not remember much about their consultations; therefore, everything must be reduced to writing to prove to them that someone informed them of their treatment. It is a monumental problem for implant dentists to treat this group of patients.

4. ***Recurrent or residual periodontal disease:*** Many of these patients have deep-seeded bacteria that are impossible to eliminate and that cause most implant problems, as well as, problems with any remaining teeth they might have.

Once the relationship is understood, the relationship between the different spirochetal diseases becomes much more obvious. They are all similar once the disease becomes chronic.

The old literature (1907)[20] shows the various forms of the Syphilis spirochete. It has a typical "cork-screw" shape, which seems to be its active form. As it transitions before death to a reproductive stage, it forms granules inside its cell body. When the cell membrane breaks down, the granules are dispersed into the body fluid for later regeneration into the viable active spirochete form. Later in 1912,[21] Hindle shows emergence of a granular "coccoid" forms from spirochetes. These protective forms are resistant to traditional antibiotic treatment. Once the spirochetes transform and retreat into the body's tissue in the granular or cystic form, it lives in relative harmony with the body until the immunity of the host is compromised or diminished. Inflammation is the most likely stimulus that triggers a transformation. Recent compelling evidence by MacDonald[22] illustrate that the Lyme disease spirochete, Borrelia Burgdorferi, has a granular and a cystic form distinct from each other. With DNA markers, he was able to show cysts containing the spirochete DNA in Alzheimer's plaques. He feels that the plaques originate from cysts of the Borrelia Burgdorferi spirochetes that cause Lyme disease.

The literature search of the old textbooks on bacteriology found only one reference (1960) about oral spirochete spores or granules. This references stated, ***external granules may become free from the cell and in old cultures, containing granular forms when examined by dark-field microscopy, have been shown to give rise to typical spirochetes on subculture to fresh medium—the granules may therefore be a stage in the life cycle of the organism***.[23] These granules appeared on their surface just prior to their death. The bacteriologist reporting this finding also reported that he observed these spores developing into duplicate spirochetes.

In more recent literature (1993) Wolf et al[24] reported quasi-multicellular bodies of Treponema denticola. They analyzed these forms using scanning electron microscopic methods. The spirochetes had four different forms: 1. Normal helical forms; 2. Twisted spirochetes, forming plaits; 3. Twisted spirochetes, forming club-like structures; 4. Spherical bodies that appear in different sizes. These researchers theorized that these forms were better able to resist adverse conditions.

In 1999, De Ciccio, et al[25] reported finding morphological variations of Treponema denticola in the form of "spherical bodies". Up to this time in history it was not known what influenced oral spirochetes to form these bodies. The authors in this paper attributed the changes to environmental stress to the spirochetes. They related their finding to periodontal disease by stating that the "spherical bodies" represent resting forms of the organisms. Their presence coincides with periods of disease quiescence or nonactive form.

METHODS AND MATERIALS

Two representative cases will show the oral spirochetal spore formation subsequent to antibiotic treatment. These two cases

were selected from patients that were microscopically diagnosed with spirochetal infections and were treated with antibiotics, traditional debridement, and irrigation with bactericidal chemicals and followed-up every three months. All the microscopic treatment sessions were recorded with a DVD recorder. Even though the morphology of these spirochetal spores was unknown at the time and not recognized during most of the treatment and follow-up microscopic sessions, a retrospective study was commenced and the video records of these patients were reviewed and revealed the presence of spirochetal spores in all cases.

Case 1: A 54 years old male with periodontal disease (Fig. 1) had his upper teeth extracted and a custom implant placed (Fig. 2). The upper implant had episodes of infections over the next twelve years that were apparently successfully treated with various antibiotics. However, infection always returned. During these years, without the aid of a microscope, it was not known whether the patient was re-infected from some outside source or whether indigenous spirochetal spores caused the re-infection. In 2007, bacterial studies were done microscopically. The results showed a spirochete infection (Figs 3 and 4). The patient was placed on antibiotics (metronidazole 500 milligrams and amoxicillin 500 milligrams three time per day for two weeks) and scheduled to remove the implant. At the end of the two weeks the patient requested, if at all possible, to save the implant. However, another microscopic examination was performed and it was concluded that the antibiotic regiment did not kill the spirochetes. The spirochetes had somehow gained a resistance to the antibiotics over the years. A culture was taken at that time and sent to the University of Southern California microbiology laboratory for culturing. The implant was then removed (Fig. 5). Several types of bacteria survived the antibiotic treatment, ***P. intermedia***, ***T. forsythia***, Campylobacter species, Fusobacteria species, and enteric gram-negative rods. The report indicated that no ***Treponema denticola*** was present, even though microscopically spirochetes were present. This evidence simply indicates that this specific spirochetal bacterium have gained resistance to the powerful antibiotics used to eradicate it and was genetically different from ***Treponema denticola*** (Fig. 6). Assuming that the patient took the entire antibiotic regiment, these spirochetes were able to survive the antibiotic treatment. Microscopic evidence of multiple spore "spherical bodies" and granular forms was found subsequent to antibiotic treatment (Fig. 7). They appear as dense granular "doughnut" shaped substance surrounded by a white halo with a hollow light refractive center. These forms are identical to the spirochetal forms described in the literature.

Case 2: A 43 years old female presented to my office for implant treatment. She had periodontal disease and bone loss (Fig. 8) and spirochetes were identified microscopically. She was treated with antibiotics (same regiment as above); however, because

Fig. 1: Patient's teeth with periodontal disease and needing multiple extractions

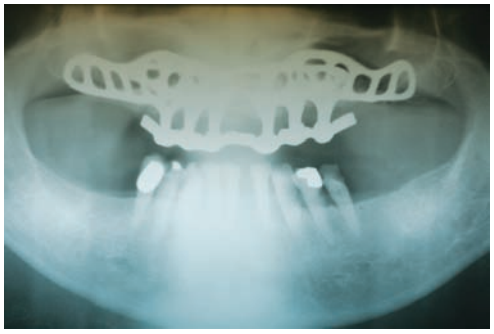

Fig. 2: An upper custom implant placed after extraction of his upper teeth

Fig. 3: At 1000X shows several spirochetes surrounding a central body

Fig. 4: At 1000X shows one granule with several spirochete attached and two cystic forms nearby

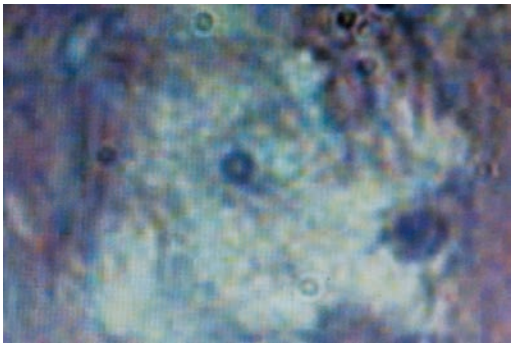

Fig. 18: Another spore from another area demonstrating that multiple spirochetes invaded this artery wall

Fig. 19: Another spore in another region of this sample

Fig. 20: One more spore

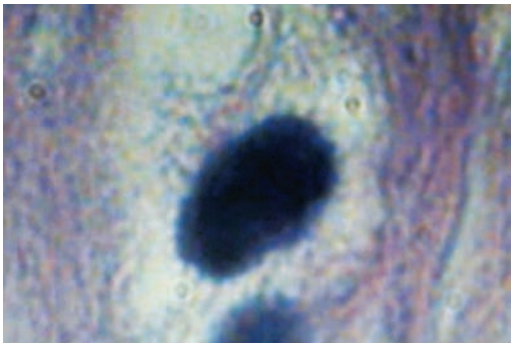

Fig. 21: A large granular structure with what appears to be multiple spirochetes radiating from the structure

DISCUSSION

The literature points out the fact that periodontal disease is related to bone loss and can cause implant failure.[26-28] Studies have shown the progression of periodontal disease in subjects who initially show no traditional signs or symptoms of periodontal disease; often have the bacteria, especially the spirochete morphogroup, in the gingival sulci. This investigation showed that patients with these types of spirochetes were three times more likely to develop periodontitis within a year in the sites tested than those that remained healthy. A distinction is made between pathogenic-related spirochetes and morphotype spirochetes. The pathogenic-related spirochetes are the most likely group to cause infection.[29,30] Unfortunately, in the clinical practice of implant dentistry, it is impossible to differentiate between these two groups of spirochetes. Based on many years of microscopic examination of bacteria populating infections associated with failing implants, many morphologic types of spirochetes have been observed. Spirochetes seem to be a "marker bacteria" in periodontal infections that cause bone loss and implant failure.

In the knowledge of (1) the recent findings reported of the relationship between periodontal disease and heart disease and (2) the implications of liability for dentists to diagnose possible sources of spirochetial bacteria that progress to periodontal disease under the right circumstances, dentists must become more vigilant in their diagnosis of spirochetes in their patient's mouth. Microscopic examination of plaque samples taken from the gingival sulci is the only method of diagnosis of these bacteria that is totally effective. Other tests, such as DNA and BANA, only test for a few of the 57 known species[31] of spirochetes. The microscope sees all of the spirochetes their spores plus their organization with other bacteria.

Another fact that is evident from these clinical cases is that even though antibiotic treatment was implemented, the bacteria can either be resistant to the antibiotic or transform into resistant forms only to return at a future time. Microscopic examinations performed one week after antibiotic treatment showed evidence of spore "spherical bodies", granular forms and possibly even cystic forms of the spirochetes. DNA studies are needed to confirm these microscopic findings.

In a medical environment where we have the benefit of antibiotics we may have become negligent in our efforts to eliminate bacteria associated with a periodontal disease. This laxity needs to end. We have an incurable disease that can be prevented, but only with extreme diligence and hard work by both the patient and the dentist. Since spirochetes can be transmitted orally from person to person via spores and also these spores can be transmitted in contaminated meat,[32-34] frequent microscopic monitoring of spirochetal bacteria by the dentist needs to be implemented in every dental office. Since

30. Riviere G, Smith K, Tzagaroulaki E, et al. Periodontal status and detection of frequency of bacteria at sites of periodontal health and gingivitis. J Periodontol 1996;67:109-15.
31. Ellen R, Galimanas V. Spirochetes at the forefront of periodontal infections. Periodontology 2000,2005;38(1):13-32.
32. Choi BK, et al. Spirochetes from digital dermatitis lesions in cattle are closely related to treponemas associated with human periodonttis. Int J Syst Bacteriol 1997;47(1):175-81.
33. Colligham RJ, et al. A spirodchete isolate from a case of severe virulent ovine foot disease is closely related to a treponema isolated from human periodontitis and bovine digital dermatitis. Vet Microbiol 2000;74(3):249-57.
34. Demirkan I, et al. Serological evidence of spirochaetal infections associated with digital dermatitis in dairy cattle. Vet J 1999; 157(1):69-77.

William D Nordquist
(wdndmd@pacbell.net)